



Spontaneous Intracapsular Tonsillar Hemorrhage

Spontan İntrakapsüler Tonsiller Kanama

Spontan Tonsiller Kanama / Spontaneous Tonsillar Hemorrhage

Güçlü Kaan Beriat¹, Cem Doğan¹, Şefik Halit Akmansu¹, Ömür Ataoğlu²

¹Ufuk University, Faculty of Medicine, Department of Otorhinolaryngolog, ²Mikro-Pat Pathology Laboratory, Ankara, Turkey

Özet

Bu vaka sunumunda sol tonsilla palatina medialine yerleşen ve bir kök ile tonsil dokusuna tutunan bir tümör görünümünde olan spontan intrakapsüler tonsiller kanama vakasını tartıştık. Hasta 30 yaşında sağlıklı bir gebe kadındı. Hastanın son üç aydır giderek artan orofarensde yabancı cisim hissi ve yutma güçlüğü mevcuttu. Hastanın akut, kronik tonsillit veya travma öyküsü yoktu. Muayenesinde sol palatin tonsil üst kutbundan küçük bir kök ile ayrılan 2 cm çapında, hareketli kahverengi kitle görüldü. Diğer laboratuvar sonuçları normaldi. Kitle genel anestezi altında eksize edildi. Histolojik değerlendirme sonucu kapsül ile çevrelenmiş, lenfoepitelial doku ve akut kanama alanları olan tonsiler intrakapsüler hemoraji olduğu sonucuna varıldı. Hastamıza doğum sonrası tonsillektomi planlandı. Bu tanı ile izlenen hastalara disfaji, kanama, aspirasyon, riski ve olası malign tümörlerden ayırt etmek amacı ile tonsillektomi yapılmalıdır.

Anahtar Kelimeler

Tonsilla Palatina; Spontan Kanama; Gebelik; Disfaji; Farengal Kitle

Abstract

In this case report, we discussed a case of spontaneous intracapsular tonsillar haemorrhage appearing as a tumor medial to the left palatine tonsil and clinging to the tonsillar tissue with a pedicle. The patient was a 30 years old healthy pregnant woman. She had a growing sensation of a lump in her oropharynx and dysphagia in the past three months. She had no history of acute and chronic tonsillitis or trauma. On examination, a mobile brown mass with a 2 cm diameter having a small pedicle at the upper pole of the left palatine tonsil was seen. Other laboratory results were normal. The mass was excised under general anesthesia. Histological evaluation revealed tonsillar intracapsular bleeding with lymphoepithelial tissue and acute hemorrhagic fields bounded by a capsule. A postpartum tonsillectomy was planned for our patient. Tonsillectomy must be performed to patients followed up with this diagnosis in order to differentiate between dysphagia, risks of bleeding and aspiration, and malignant tumors.

Keywords

Palatine Tonsil; Hemorrhage; Spontaneous; Pregnancy; Dysphagia; Pharyngeal Mass

DOI: 10.4328/JCAM.524

Received: 07.12.2010

Accepted: 03.01.2011

Printed: 01.07.2012

J Clin Anal Med 2012;3(3): 347-9

Corresponding Author: Cem Doğan, Mevlana Bulvarı No: 86 Balgat/ Ankara, Turkey.

T.: +90 3122044175 F.: +90 3122872390 E-Mail: cemdo78@yahoo.com

Introduction

Infectious inflammation of the tonsil can lead to vessel erosions. It is reported that the incidence of significant hemorrhagic complications of infectious tonsillitis is about 1.1% [1]. During the period before the use of antibiotics, spontaneous acute tonsillar haemorrhage was associated with peritonsillar abscess [2]. β -haemolytic streptococcus, staphylococcus and actinomyces infections have been shown to be the cause of spontaneous tonsillar haemorrhage [3-9]. Moreover, spontaneous tonsillar bleeding is described as a complication of infectious mononucleosis and measles [10].

Spontaneous tonsillar haemorrhage of non-iatrogenic origin is rare in the literature. Spontaneous intratonsillar hemorrhage of undetermined cause reported in the literature was limited to a single case [3-11].

We report a healthy six months pregnant patient with spontaneous intratonsillar haemorrhage not associated with any apparent cause, causing dysphagia due to an enlarged lobe of the superior pole of left tonsil protruding into the oropharynx.

Case Report

A 30-year-old healthy woman with six months pregnancy and without history of acute or chronic tonsillitis, presented with an approximately three months history of dysphagia accompanying a foreign body sensation.

Physical examination revealed a mass protruding from the superior pole of tonsillar tissue at left anterior tonsillar pillar level. The mass appeared to be 2 x 2 x 3 cm in diameter, sessile, mobile, of shiny brown colour, smoothly overlying mucosal layer, easily degradable, tonsil like tissue. Both palatine tonsils were normal (Figure 1). The patient was complaining of severe vomiting in the first months of pregnancy. She had fissura linguata and she was allergic to strawberries and eggplant. In addition, it was learned that when the patient consumed some foods, edema and hyperemia of the tongue emerged and the fissures of the tongue became deeper. There were no palpable cervical adenopathies.

The preoperative laboratory blood and bleeding test parameters were proved to be normal. Magnetic resonance imaging of the head revealed the presence of a non-calcified oval mass measuring approximately 2 x 2 x 3 cm. No other pathologies peritonsillar and neck region.

Operations were performed under general anesthesia. The mass was excised, and cauterized by bipolar cautery (Figure 2). Patient was discharged on the first day after the operation.

Histologic observation of the specimen showed a regular parenchymal structure with an intact capsule and intracapsular bleeding. Histopathological investigation confirmed the pres-

ence of regular lymphoepithelial tissue. The minor hypertrophic lymphoid tissue appeared normal except for an interfollicular edema (Figure 3).

In this case we found a tumor-like lesion that histologically proved to be hypertrophic tonsillar tissue with acute intraparenchymal bleeding.

Discussion

Spontaneous tonsillar hemorrhage is the bleeding of intact tonsils, diagnosis when iatrogenic causes or surgical causes have been ruled out [1]. There are various pathologic conditions associated with spontaneous tonsillar hemorrhage, including acute or chronic tonsillitis, peritonsillar or parapharyngeal abscess, infectious mononucleosis, carotid aneurysm or pseudoaneurysm, tonsil cancer, etc [1].

The most common cause of spontaneous tonsillar hemorrhage is bacterial or viral infection; it is rarely associated with a malignancy or coagulopathy [1,12]. Evaluation for bacterial tonsillitis, viral infection (including measles, infectious mononucleosis, and others), peritonsillar or other space occupying abscess, as well as cancer of the tonsils should be carried out [1,12-14].

It is possible that inflammation of the tonsils results in increased blood flow to the tonsils and then necrosis or trauma of the congested tonsillar vessels leads to spontaneous tonsillar hemorrhage [12].

As in this case, sometimes extravasating blood is trapped inside the tonsil, coagulates, and by time becomes capsulated. The etiology and pathogenesis are unknown. Theoretical speculations can be made according to limited data.

We theorize that malformation of tonsil developed embryologically, and an ensuing infection or trauma resulted in increased swelling of malformed tonsils, especially by repeated infection, inflammatory diseases, hemorrhagic diastesis, edema and hormonal changes. This can cause loss of connective tissue around vessels resulting in repeated intraparenchymal bleeding, which then forms a tumoral mass. However, we did not find any report of a comparable anatomic abnormality of both tonsils and subsequent intratonsillar bleeding resulting in a tumor.

Local inflammation causes an increased permeability of the vessel walls due to the local cellular secretion of inflammation mediators (e.g. histamin, kinine, serotonin and prostaglandine) induced by allergic mediators binding to cell receptors. White blood cells like antibodies and lymphocytes as well as tissue fluid are forced into the extravascular space causing an intraparenchymal swelling, which in turn induces reverse compression of local vessels within the inflamed area. Hormonal changes in pregnancy can contribute to edema and intraparenchymal swelling

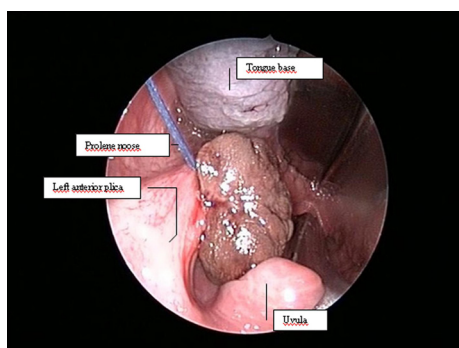


Figure 1. View of the mass inside the mouth

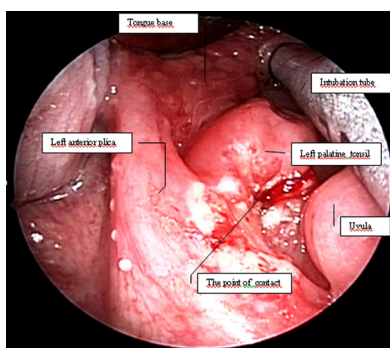


Figure 2. View of the inside of the mouth after excision of the mass

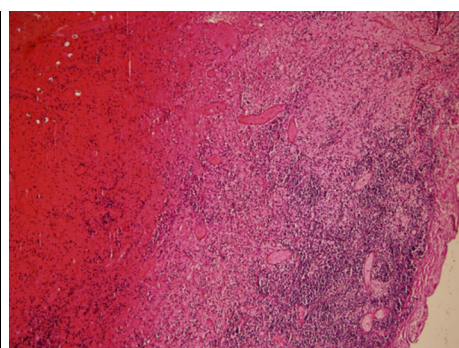


Figure 3. Microscopic appearance of the mass (H.E., 2x100): Respectively, inwards from the mass; tonsillar capsule, fibrotic layer and bleeding area.

Patients' allergic evaluation is postponed to postpartum period. Another possible cause is the defect in coagulation system which cannot be determined by routine coagulation tests like prothrombin time, coagulation time, etc.

In our case, laboratory tests were carried out to rule out rare coagulation anomalies and test results were found normal. Hereditary hemorrhagic telangiectasias can cause such situations; but in our patients' relatives, a history of intracranial or internal organ bleeding did not exist.

Another aspect in our case may be the presence of microorganisms such as actinomyces and bacteria like streptococci and staphylococci in the tonsillar crypts that cause inflammation [15]. In previous studies no correlation between the clinical diagnosis of tonsillar disease and the presence of actinomyces could be observed [4]. Our patient's throat culture showed normal throat flora.

Some authors reported that minor tissue response is due to the fact that actinomyces are saprophytes rather than primary pathogens; hence they do not cause recurrent acute tonsillitis [16,17]. In accordance with this observation, our patient had no history of recurrent tonsillitis.

What is dangerous in these cases is a possible uncontrolled bleeding with ongoing life threatening blood loss and aspiration [18]. So, the priority in treatment is to determine the bleeding focus and supplying vessel. Angiogram, CT, or MRI must be carried out and the surgery needed is determined accordingly. In our case patient was pregnant and MRI was carried out to avoid contrast material. The mass was a solid mass limited to the tonsil and was not involved with carotid arteries.

It was decided to surgically resect the mass in order to avoid sudden bleeding, respiratory pathway obstruction, and possibility of malignancy. General anesthesia was safer for both the patient and the surgeon. Excision of the mass and cauterization, a short time taking and low-risk surgery option was preferred. Tonsillectomy is suggested for these cases for the possibility of underlying malignancy and potential repeated bleeding. In our case we did not prefer surgery. As the patient was pregnant, we preferred to avoid the morbidity and complications.

Our case has no etiologic similarity with the cases in literature. The dissimilarities in our case are six month pregnancy, serious vomiting, food allergy and the presence of fissura linguata. Extravasation and vascular damage which are assumed to be due to infection, can be a result of hormonal changes during pregnancy, vomiting due to trauma and allergy as in our case.

As the surgery was not performed, bleeding and malignancy are still probable. So we are following-up the patient with her obstetrician. We planned postpartum tonsillectomy.

References

1. Griffies WS, Wotowic PW, Wildes TO. Spontaneous tonsillar hemorrhage. *Laryngoscope*. 1988; 98(4):365-8.
2. Salinger S, Pearlman SJ. Haemorrhage from pharyngeal and peritonsillar abscess. *Arch Otolaryngol* 1933;18(4):464-509
3. Siedek V, Reichel O, Harr us U. Spontaneous intratonsillar haemorrhage with acute dysphagia. *Eur Arch Otorhinolaryngol*. 2008;265:721-723.
4. Aydin A, Erkilic S, Bayazit YA, Kocer NE, Ozer E, Kanlikama M. Relation between actinomycosis and histopathological and clinical features of the palatine tonsils: a comparative study between adult and pediatric patients. *Rev Laryngol Otol Rhinol*. 2005; 126(2):95-98
5. Dawlatly EE, Satti MB, Bohlga LA. Spontaneous tonsillar haemorrhage: an underdiagnosed condition. *J Otolaryngol*.1998;27(5):270-274
6. Jawad J, Blayney W. Spontaneous tonsillar haemorrhage in acute tonsillitis. *J Laryngol Otol*.1994;108:791-794
7. McCormick MS, Hassett P. Spontaneous haemorrhage from the tonsil (a case report). *J Laryngol Otol*.1987;101(6):613-616
8. Sayed K, Van Savell H Jr, Hutchison RE, Kepner J, Link MP, Schwenn M, Mahmoud H, Parham DM. Review of tonsillar lymphoma in pediatric patients from the pediatric oncology group: what can be learned about some indications for microscopic

examination. *Pediatr Dev Pathol*. 2005; 8(5):533-540.

9. Shatz A. Spontaneous tonsillar bleeding secondary to acute tonsillitis in children. *Int J Pediatr Otorhinolaryngol*.1993;26(2):181-184

10. John DG, Thomas PL, Semearo D. Tonsillar haemorrhage and measles. *J Laryngol Otol*. 1988;102(1):64-66

11. Vaughan MM, Parker AJ. Idiopathic spontaneous tonsillar haemorrhage. *J Laryngol Otol*. 1993;107(1):44-45

12. Levy S, Brodsky L, Stanievich J. Hemorrhagic tonsillitis. *Laryngoscope* 1989; 99(1):15-8.

13. John DG, Thomas PL, Semeraro D. Tonsillar haemorrhage and measles. *J Laryngol Otol*. 1988;102(1):64-6.

14. Kumra V, Vastola AP, Keiserman S, Lucente FE. Spontaneous tonsillar hemorrhage. *Otolaryngol Head Neck Surg*. 2001;124(1):51-2.

15. Brook I, Yocum P. Bacteriology of chronic tonsillitis in young adults. *Arch Otolaryngol*. 1984;110(12):803-805

16. Gavney R, Harrison M, Walsh M, Sweeney E, Caverkey M. The incidence and role of actinomyces in recurrent acute tonsillitis. *Clin Otolaryngol*.1993;18:268-271

17. Maher A, Bassioun A, Bucci TJ, Moawald MK, Hendawy DS. Tonsillomycosis: a myco-histopathological study. *J Laryngol Otol*.1982;96:229-240

18. Skinner DW, Chui P. Spontaneous tonsillar haemorrhage: (two cases). *J Laryngol Otol*. 1987;101 (6):611-612